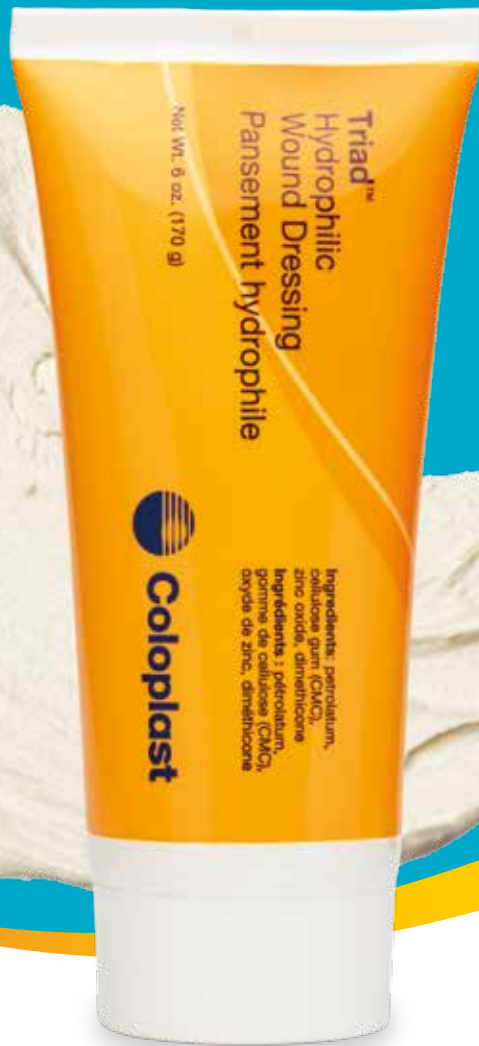

Triad®

Hydrophilic Wound Dressing

Case Studies



Net Wt. 6 oz. (170 g)

Triad™
Hydrophilic
Wound Dressing
Pansement hydrophile



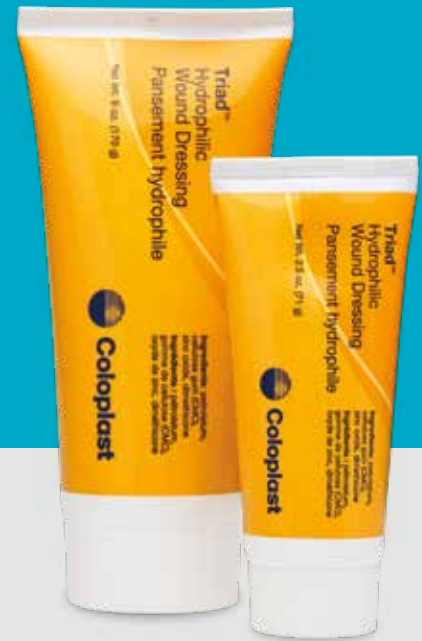Coloplast

Ingredients: petrolatum,
cellulose gum (CMC),
zinc oxide, dimethicone
Ingredients: pétrolatum,
gomme de cellulose (CMC),
oxyde de zinc, diméthicone

Triad®

Hydrophilic Wound Dressing

Manage *difficult-to-dress* wounds with Triad®



Impact of *difficult-to-dress* wounds

On wet or irregular surfaces, wound dressings may not always stay in place. Frequent dressing replacements could lead to:



Avoidable costs
related to using
extra dressings



Increased workload
for nurses replacing
multiple dressings



Delayed wound healing
impacting the total
cost of care

A *unique* approach

Triad Hydrophilic Wound Dressing is a sterile coating that offers a unique approach to difficult-to-dress wounds.



Apply anywhere

Triad is easy to apply, directly from the tube onto the wound or periwound skin, anywhere on the body.



Adheres to wet skin

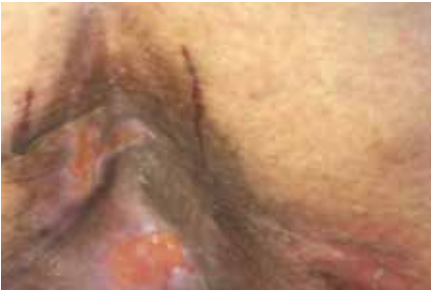Triad adheres to wet or dry skin and consistently stays in place, even in the presence of incontinence or maceration.



Keeps the wound covered

Triad creates a moist wound environment that facilitates healing and autolytic debridement.

Indications for Triad

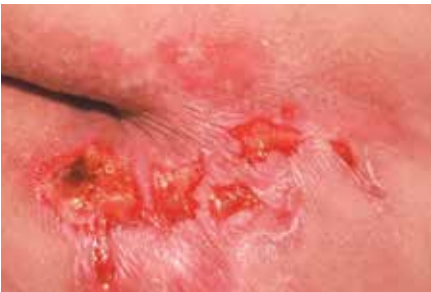

Wounds on *irregular surfaces*

Triad is designed to be applied directly from the tube onto the wound without the need for a secondary dressing.

Irregular surfaces could include the gluteal cleft, coccyx, perineum, buttocks, groin, face, hands, feet and other areas.

Triad is easy to apply and can be used on the wound and/or periwound skin.

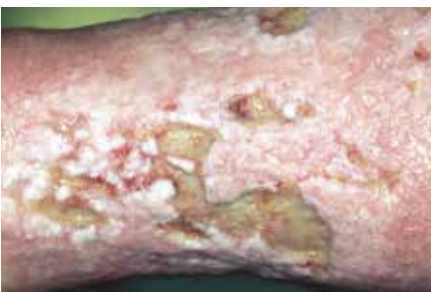

Broken skin in the presence of incontinence

Triad is a sterile coating that can be used on broken skin.

CMC allows Triad to adhere to wet skin, keeping the wound covered and protected from incontinence.

Triad contains dimethicone to moisturize the skin and petrolatum and zinc oxide to reduce skin irritation.

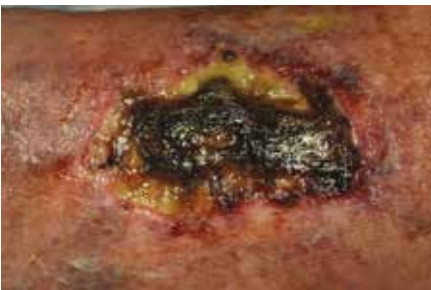

Maceration of periwound skin

Triad is easy to use on large surfaces and can be used on the wound and periwound skin.

CMC allows Triad to adhere to macerated skin, keeping it covered and protected from wound exudate.

Triad contains dimethicone to moisturize the skin and petrolatum and zinc oxide to reduce skin irritation.



Necrotic tissue such as slough or eschar

Triad is hydrophilic, which means that natural moisture spreads evenly across the wound surface, maximizing contact and creating a moist environment.

A moist wound environment facilitates autolytic debridement, where the body's own enzymes break down necrotic tissue.

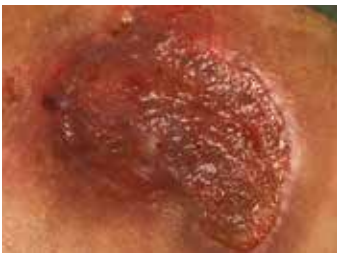CMC allows Triad to absorb low to moderate levels of wound exudate or broken-down tissue.

Wounds on irregular surfaces

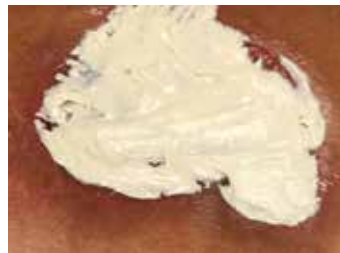Wounds on irregular surfaces can be challenging because dressings may not stay in place. Some shapes, sizes and locations of wounds can make them difficult-to-dress. All dressings may not contour to the curves of the body, fit the shape of the wound or withstand frequent movement. Triad® is a unique approach to difficult-to-dress wounds.

Wound on shoulder from an accident

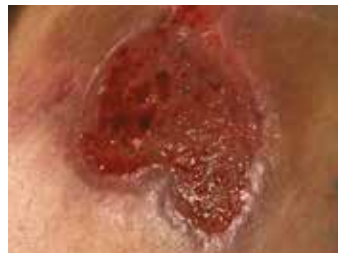41-year old male with an open wound on his shoulder, a location that was difficult to keep a dressing in place. Triad was easy to apply, soothing, and absorptive of the small volume of drainage from the wound.



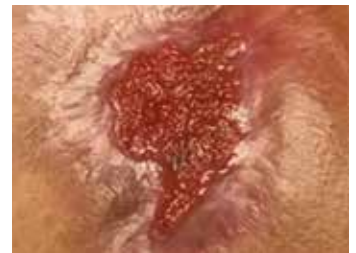DAY 1
Wound is 7.5cm x 5.5 cm and difficult to keep a dressing in place.



Triad is applied to the wound bed.



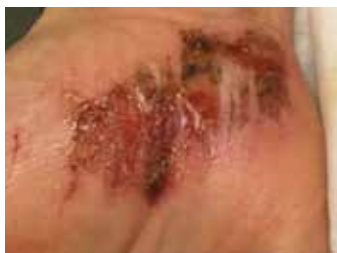DAY 6
Wound is less painful during dressing changes.



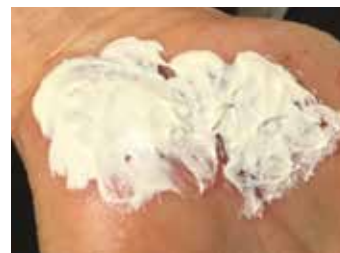DAY 20
Wound is significantly smaller, 4.5 cm x 2.5 cm and no longer painful during dressing changes.

Road rash on wrist and elbow

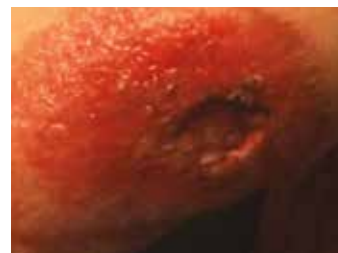71-year old female with road rash on her arms, hands and face due to a bike accident. She was in extreme pain two days after the accident. Triad was applied to the wound bed and periwound skin.



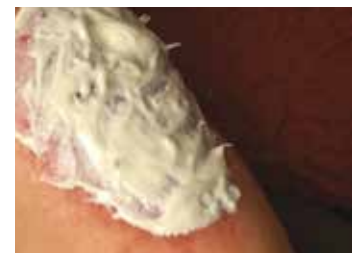Wound as presented on Day 2.



Triad is applied to the wound bed.



Wound as presented on Day 2.



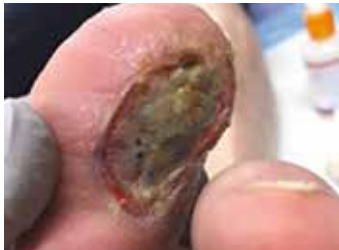Triad is applied to wound bed and periwound skin.

"After 1 application of Triad, wound was progressing and the patient was able to continue to use Triad at home for wound treatment."

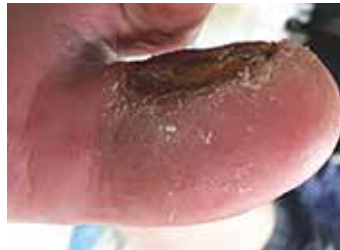— JULIE FREYBERG, CWOON, MANKATO CLINIC

Diabetic foot ulcer on the toe

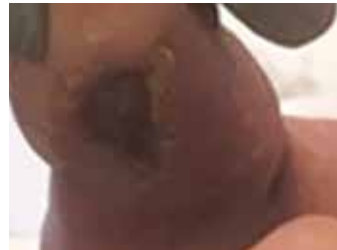65-year old male with a diabetic foot ulcer. No infection. Treatment included a variety of other products first that failed to close the wound. To achieve a moist wound healing environment, Triad was applied.



WEEK 1
Foot ulcer in a difficult-to-dress location.



WEEK 2
Triad stayed in place to maintain a moist wound healing environment.



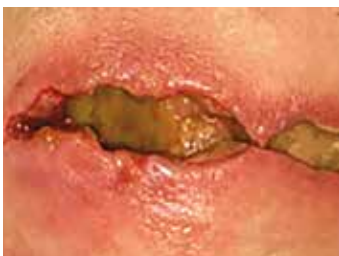WEEK 3
Slough removed from the wound and progressing toward full closure.



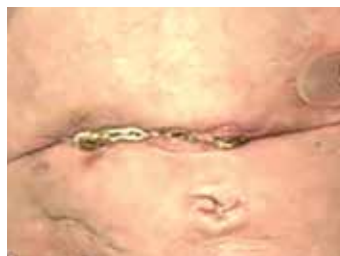Scan the QR code to view video.

Wound dehiscence on neonate stomach¹

Surgical NICU patient after abdominal surgery with wound dehiscence. Treatment included Triad, stoma paste and a bordered foam dressing.



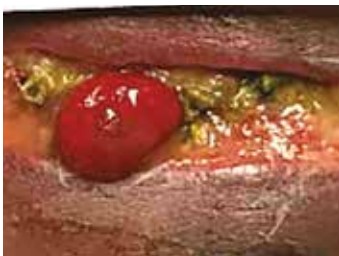DAY 1
The wound bed is filled with Triad using a syringe.



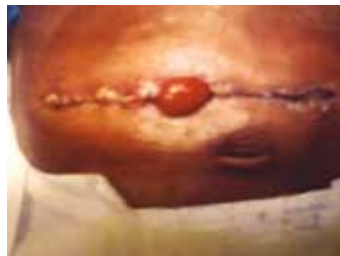DAY 16
Wound is fully closed.

Wound dehiscence on neonate stomach¹

Surgical NICU patient after abdominal surgery with wound dehiscence. Wound care was complicated by the existence of an ileostomy stoma in the middle of the incision. Treatment included Triad, stoma paste and a bordered foam dressing. Using Triad reduced frequency of dressing changes from multiple per day to intervals extending up to every 3 days.



DAY 1
The wound bed is filled with Triad using a syringe.



DAY 23
Wound is fully closed.

Triad is suitable for neonates.

"When people see a large dressing on a neonate, they get a bit upset. When they see Triad on a neonate, they know it's actually a smaller wound."

— DR. HOLLY KIRKLAND-KYHN,
DIRECTOR OF WOUND CARE,
UC DAVIS MEDICAL CENTER

1. Hydrophilic Paste as Primary Dressing for Abdominal Wound Dehiscence in the Neonate, South Central WOCN Region Conference, 2019

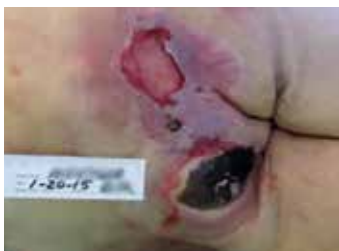Broken Skin in the presence of incontinence

Wounds in areas exposed to moisture (i.e. urine and stool) are not always easy to manage. Dressings do not always stick to wet skin and stay in place. Triad® is able to adhere to wet skin.

Sacral ulcer in the presence of incontinence

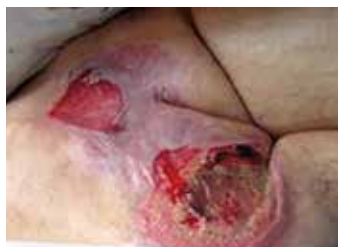65-year old male with a chronic sacral ulcer over two years duration. Unable to maintain a dressing due to multiple bloody stools and urinary incontinence.

- Malnutrition, C. difficile colitis, type 2 diabetic, sigmoid colon adenocarcinoma, acute kidney injury, smoker, failure to thrive, history of fall
- Nutrition – NPO on TPN; hemoglobin 8.6; total protein 4.6; albumin 1.8
- Treatment included nutrition consult, standard pressure ulcer preventative measures and application of Triad hydrophilic wound dressing to unstageable sacral and ischial pressure ulcers
- Left ischial ulcer with epithelial tissue and coccyx epithelial tissue with 1 cm opening



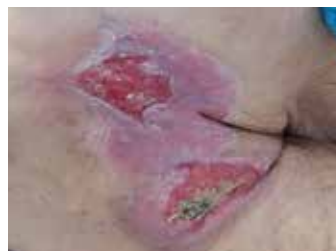WEEK 1

Triad is applied to unstageable sacral and ischial pressure ulcers.



WEEK 2

Triad has supported autolytic debridement.



WEEK 3

Pressure ulcers are progressing toward healing.



Scan the QR code to view video.

"This wound had been present for 2 years. All dressings failed because of frequent episodes of incontinence. Triad was used for protection from urine and stool, providing a moist wound healing environment and for debridement."

— DOROTHY DOUGHTY, CWOCN,
DIRECTOR OF WOC NURSING EDUCATION,
EMORY UNIVERSITY

Child with broken skin due to incontinence

3-year old boy with broken skin on his buttocks and inner thighs.
Patient on the oncology floor undergoing chemotherapy treatment that causes liquid stool.

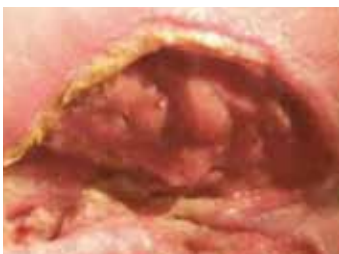Scan the QR code
to view video.



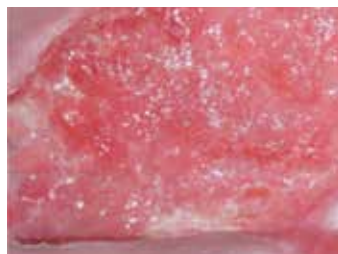<p>Skin is red, shiny, moist and denuded tissue. The top layer of skin is no longer intact.</p>	<p>After trying many other topical treatments, Triad is applied to the buttocks and inner thighs.</p>	<p>Immediately, the patient experienced relief and skin was less irritated.</p>	<p>After 1 week, the skin was no longer shiny red, but it was healed and intact tissue.</p>
<p>AFTER MANY WEEKS</p>	<p><i>Triad is applied</i></p>	<p>DAY 1</p>	<p>WEEK 1</p>

Sacral pressure injury in presence of incontinence

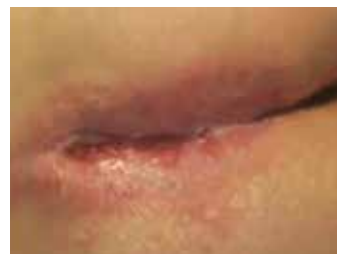65-year old white male with a sacral pressure injury, present for 3.5 months. Prior medical history: Peripheral vascular disease, fecal incontinence, indwelling catheter secondary to urinary incontinence, limited mobility. Resides at an ECF. Prior treatment: Clostridial collagenase ointment (CCO) with normal saline-moistened gauze daily x9 days. Triad implemented.



DAY 1
Treatment with CCO, saline-moistened gauze and ABD pad. Dressing change frequency: Every 12 hours



DAY 22
Triad is applied, antimicrobial gauze covered with ABD pad. Dressing change frequency: 3x/week



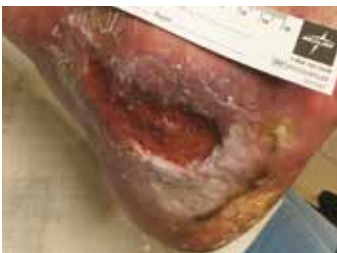DAY 122
Greater than 90% wound closure. Triad is re-applied every 3 days.

Maceration of the periwound skin

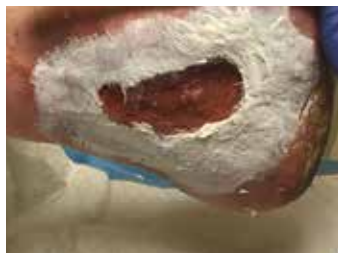Some wound dressings may cause exudate to spread and pool on the periwound skin. This can cause maceration. Triad® can be applied directly to the periwound skin.

Venous leg ulcer with maceration

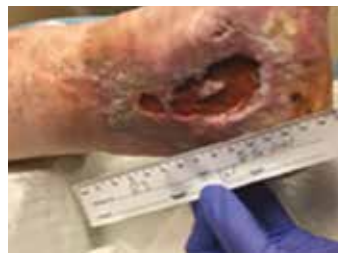68-year old male with a chronic venous leg ulcer near his ankle. The periwound skin is very damaged and macerated. Triad is applied to the periwound skin.



DAY 1
White, macerated periwound skin.



Triad is applied to periwound skin.



DAY 27
Periwound skin is improving and the wound bed is smaller.



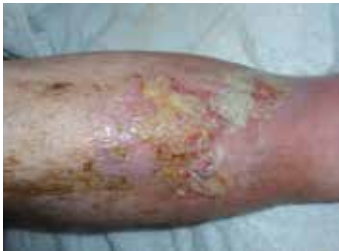Scan the QR code to view video.

"Triad is so helpful because it's thick enough to stay in place, it absorbs a little bit of drainage and it protects the skin."

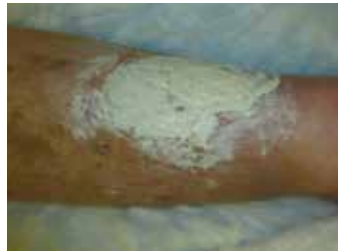— JULIE FREYBERG, CWOCN, MANKATO CLINIC

Lower leg wound due to lymphedema

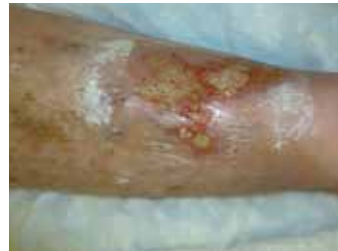60-year old male with wounds on his left leg due to lymphedema. Petrolatum dressing was applied first. Upon removal, extensive periwound maceration was noted. Triad was applied and within 48 hours of staying in place, maceration was resolved.



DAY 1
Extensive periwound skin breakdown and maceration.



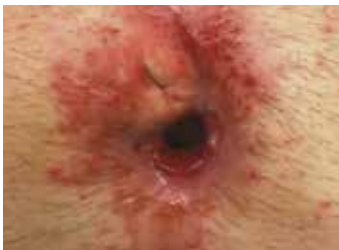Triad is applied to wound and periwound skin.



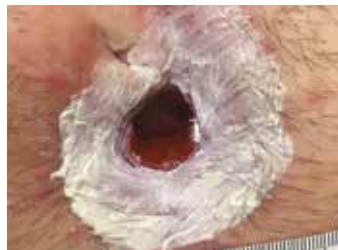DAY 2
Maceration has resolved after 48 hours of using Triad.

Abdominal wound with maceration

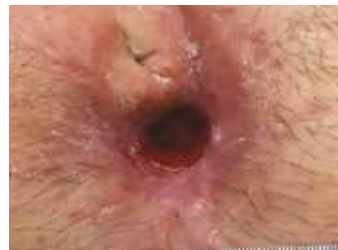51-year old male with an abdominal wound post-colectomy that had been present for 2 months. Past treatment included negative pressure, collagen and bordered foam dressings. He was sensitive to adhesives and had some drainage so the periwound skin was getting damaged. Triad was applied to help with drainage.



DAY 1
Skin itching and irritation of the periwound skin.



DAY 3
Triad has stayed in place since Day 1.



DAY 3
Triad is removed. It was soothing, allowed for healing and resolved pruritus. Patient had less anxiety about the wound and dressing.



Scan the QR code to view video.

Necrotic tissue such as slough or eschar

It is well documented that the presence of devitalized tissue in a wound interferes with wound healing and requires debridement.¹ Not all debridement methods are suitable and/or available within different healthcare settings. Triad[®] can facilitate autolytic debridement.

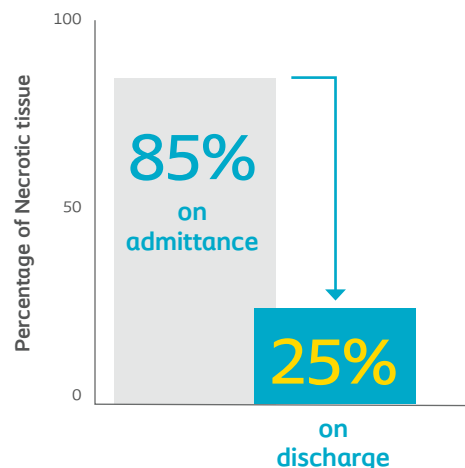
Triad Supports Autolytic Debridement

**North Shore Medical Center Wound Care
Boston, MA**

In a trial on 12 patients,² Triad was evaluated as an alternative to silicone foam dressings in difficult-to-dress areas.

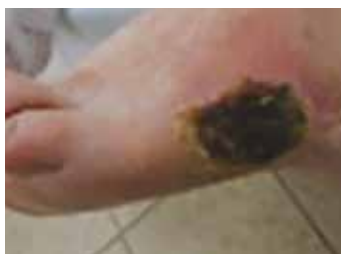By staying in place, Triad was able to create a moist wound environment, promoted autolytic debridement and thereby reduced necrotic tissue.

On average, the amount of necrotic tissue in the wound bed was reduced from 85% on admission to 25% on discharge.

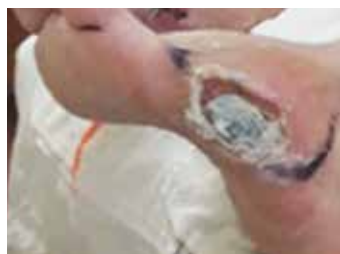

Diabetic foot ulcer with necrotic tissue

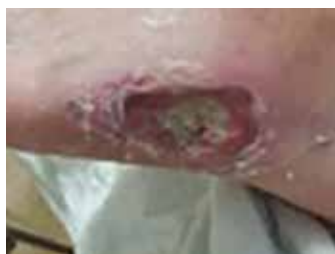72-year old female with a diabetic foot ulcer. No infection and no osteomyelitis confirmed by a bone scan. Medical history includes Type 2 Diabetes and arterial insufficiency. Patient declines surgical debridement. Treatment included impregnating gauze with Triad and applying Triad over the top of the wound bed to loosen the eschar. Wound was seen daily.



DAY 1
Diabetic foot ulcer with dry, mobile black eschar.



DAY 4
Triad has stayed in place to support autolytic debridement.



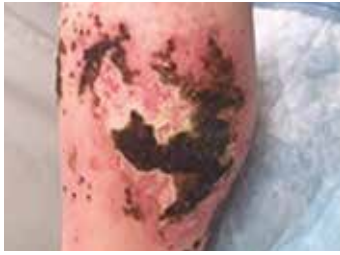DAY 7
Black eschar is no longer in the wound bed. It is progressing toward healing after 7 days with Triad in place.

1 Ramundo JM. Principles and guidelines for wound debridement. In: Doughty, DB, McNichol LL, eds. Wound, Ostomy and Continence Nurses Society Core Curriculum Wound Management. Philadelphia, PA: Wolters Kluwer; 2016:145-155.

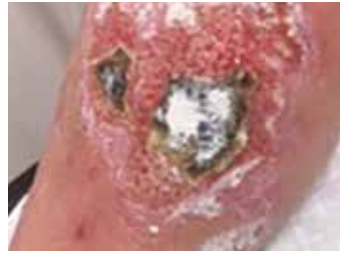2 An examination of a hydrophilic zinc oxide-based paste dressing for use in difficult-to-dress wounds, 47th WOCN Society Annual Conference, 2015.

Venous leg ulcer with necrotic tissue

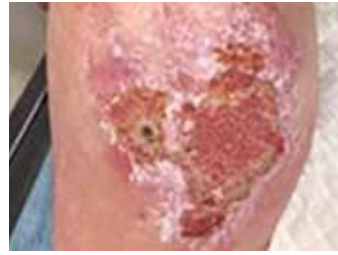60-year old male with a venous leg ulcer. Medical history includes vasculitis. Treated with Triad to support autolytic debridement along with steroids initiated orally.



DAY 1
Wounds with thick black eschar.



DAY 3
Triad is supporting autolytic debridement.



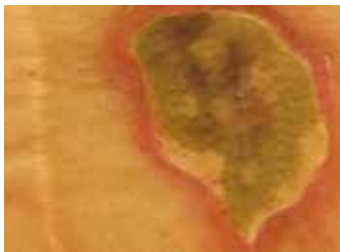DAY 7
Wound bed with granulated tissue and no black eschar remaining.



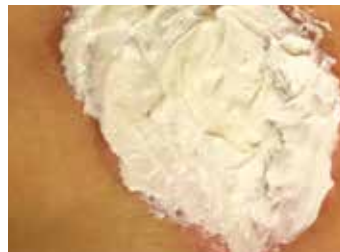Scan the QR code to view video.

Open wound with slough on the lower back

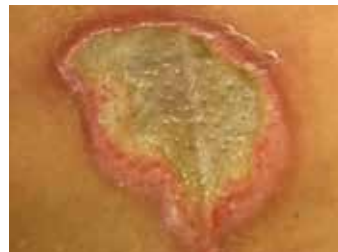66-year old female with a wound on her lower back. No notable comorbidities. Painful wound that was managed by hydrocortisone, silvadene and vaseline prior to using Triad.



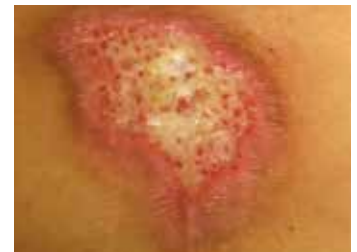DAY 1
Slough in the wound bed.



Triad is applied to the wound bed.



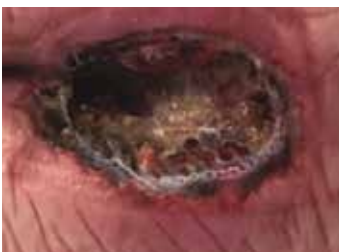DAY 7
Percentage of wound bed with slough has declined.



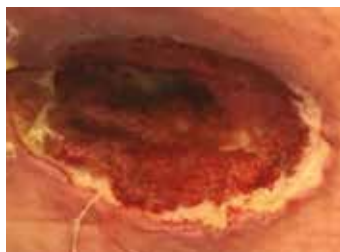
DAY 21
Most slough is no longer in the wound bed. Granulation tissue is present.

Unstageable pressure ulcer in the gluteal cleft

67-year old female was discovered unconscious at home. She developed numerous unstageable pressure injuries. Medical history includes Korsakoff syndrome and ETOH related dementia or confusion. Due to her comorbidities, surgical debridement was not an option. Pressure injuries were treated with Triad. Triad supported autolytic debridement and a bit of conservative debridement with tweezers was performed.



WEEK 1
Pressure injury with slough and eschar.



WEEK 2
Fully debrided wound bed with new granulation tissue.

A cost-effective solution

It is well documented that the presence of devitalized tissue in a wound interferes with wound healing and requires debridement. Enzymatic debridement is an effective method of debridement, but in some cases it can be cost-prohibitive. In addition to the cost, the accessibility of this form of debridement can affect timely application for those residing in alternate care settings or at home.

A comparison of wound management cost and outcomes with a hydrophilic wound dressing* versus a clostridial collagenase ointment† (CCO).

Denice R. Taylor
MSN, ET, CNP, CWOCN
Columbus, OH

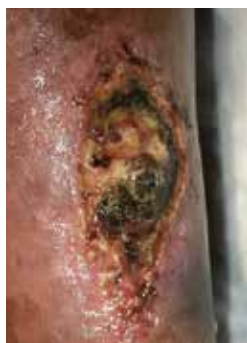The following case series compares the cost and effectiveness of debriding a wound with a clostridial collagenase ointment† (CCO) compared to a zinc oxide-based hydrophilic wound dressing.*

Conclusion

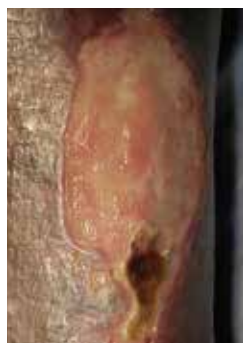The use of a zinc oxide-based hydrophilic wound dressing* is both cost-effective and highly effective in promoting a moist wound environment to facilitate autolytic debridement.

Venous stasis ulcer

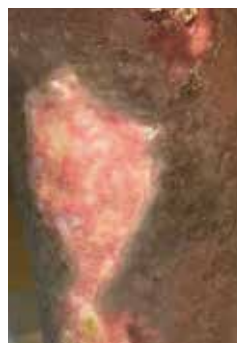56-year-old African-American male with a right posterior calf venous stasis ulcer. Prior medical history: Lower extremity peripheral vascular disease (mixed disease; venous and arterial), and type 2 diabetes. Ulcer present for 5 months. Resides at home. Prior treatment: Clostridial collagenase ointment† (CCO) with normal saline-moistened gauze every 12 hours x10 weeks. Hydrophilic wound dressing* implemented on 09/15/15. Admitted to an extended care facility and lost to follow up.



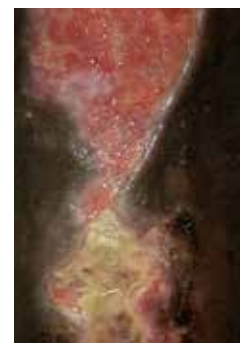DAY 1
 Treatment with CCO, saline-moistened gauze and ABD pad. Dressing change frequency: Every 12 hours



DAY 24
 Treatment with CCO continued. Dressing change frequency: Every 12 hours



DAY 71
Triad® is applied.
 Covered with ABD pad. Dressing change frequency: 3x/week



DAY 85
 Slough and eschar are decreasing in the wound bed. Dressing change frequency: 3x/week

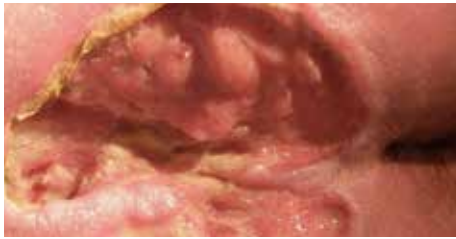
Cost comparison for 15 days

Dressing	Amount needed	Cost per tube	Total cost
Clostridial collagenase ointment† (CCO)	120 gms/Four 30-g tubes	\$290.25	290.25 x 4 = \$1,161.00
Hydrophilic wound dressing*	One 6 oz. (170 gm) tube	\$23.71	23.71 x 1 = \$23.71

Amount of CCO† determined by entering wound length, wound width and duration of therapy into dosing calculator found at HYPERLINK "<http://www.santyl.com/hcp/dosing-calculator>" (accessed on May 30, 2019). Use of CCO† should be terminated when debridement is complete and granulation tissue is well established. Found at HYPERLINK "<http://www.santyl.com/hcp/application>" (accessed on May 30, 2019). Retail costs determined from local pharmacy. Prices may vary.

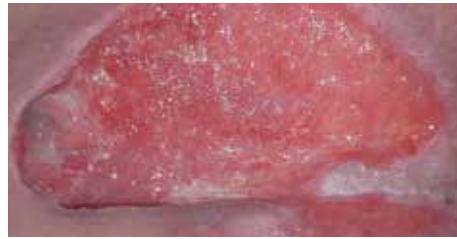
Sacral pressure injury

65-year-old white male with a sacral pressure injury, present for 3.5 months. Prior medical history: Peripheral vascular disease, fecal incontinence, indwelling catheter secondary to urinary incontinence, limited mobility. Resides at an ECF. Prior treatment: Clostridial collagenase ointment† (CCO) with normal saline-moistened gauze daily x9 days. Hydrophilic wound dressing* implemented on 12/09/15.



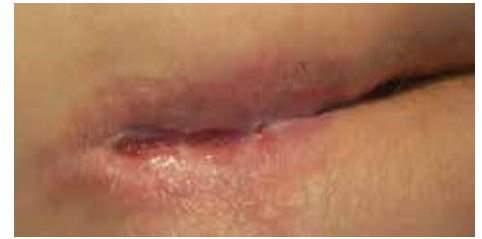DAY 1

Treatment with CCO, saline-moistened gauze and ABD pad. Dressing change frequency: Every 12 hours



DAY 22

Triad is applied, antimicrobial gauze covered with ABD pad. Dressing change frequency: 3x/week



DAY 112

Greater than 90% wound closure. Triad is re-applied every 3 days.

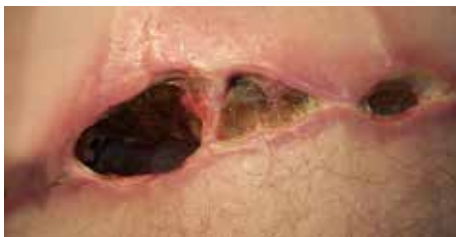Cost comparison for 22 days

Dressing	Amount needed	Cost per tube	Total cost
Clostridial collagenase ointment† (CCO)	150 gms/Five 30-g tubes	\$290.25	290.25 x 5 = \$1,451.25
Hydrophilic wound dressing*	One 6 oz. (170 gm) tube	\$23.71	23.71 x 1 = \$23.71

Amount of CCO† determined by entering wound length, wound width and duration of therapy into dosing calculator found at HYPERLINK "<http://www.santyl.com/hcp/dosing-calculator>" (accessed on May 30, 2019). Use of CCO† should be terminated when debridement is complete and granulation tissue is well established. Found at HYPERLINK "<http://www.santyl.com/hcp/application>" (accessed on May 30, 2019). Retail costs determined from local pharmacy. Prices may vary.

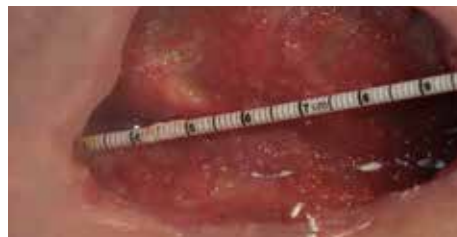Non-healing surgical wound

46-year-old white female. Non-healing surgical wound secondary to pannectomy x1 month. History of obesity. Resides at home. Prior treatment: Clostridial collagenase ointment† (CCO) with normal saline-moistened gauze daily x1 week. Hydrophilic wound dressing* implemented on 09/17/15.



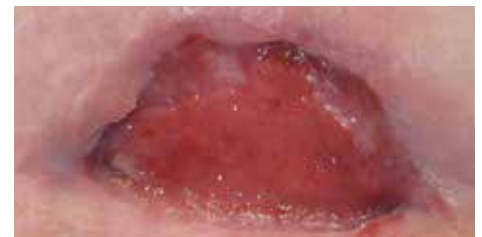DAY 1

100% necrotic tissue. *Triad is applied*. Dressing change frequency: 3 to 4x/week



DAY 26

Granulation tissue present. Dressing change frequency: 2 to 3x/week



DAY 54

Granulation tissue is now well-established. Dressing change frequency: 2 to 3x/week

Cost comparison for 26 days

Dressing	Amount needed	Cost per tube	Total cost
Clostridial collagenase ointment† (CCO)	150 gms/Five 30-g tubes	\$290.25	290.25 x 5 = \$1,451.25
Hydrophilic wound dressing*	One 6 oz. (170 gm) tube	\$23.71	23.71 x 1 = \$23.71

Amount of CCO† determined by entering wound length, wound width and duration of therapy into dosing calculator found at HYPERLINK "<http://www.santyl.com/hcp/dosing-calculator>" (accessed on May 30, 2019). Use of CCO† should be terminated when debridement is complete and granulation tissue is well established. Found at HYPERLINK "<http://www.santyl.com/hcp/application>" (accessed on May 30, 2019). Retail costs determined from local pharmacy. Prices may vary.

Product notation:

* Triad® Hydrophilic Wound Dressing, Coloplast Corp.

† Collagenase SANTYL Ointment®, Smith & Nephew, Inc.

Frequently asked questions

Triad® Hydrophilic Wound Dressing

What are the indications and contraindications of Triad?

Triad is indicated for the local management of partial- and full-thickness pressure and venous stasis ulcers, dermal lesions/injuries, and first and second-degree burns. Triad is contraindicated for third degree burns and infected wounds. Triad is only sterile on first application.

Triad is an ideal dressing choice for difficult-to-dress wounds on wet or irregular surfaces. Irregular surfaces could include the gluteal cleft, coccyx, perineum, buttocks, groin, face, hands, feet and other areas. Triad adheres to wet skin, and can be used on broken skin in the presence of incontinence, or maceration of the periwound skin. Triad facilitates autolytic debridement to help manage necrotic tissue such as slough and eschar.

How does Triad work?

Triad can be used on the wound or periwound skin, and stays in place on irregular surfaces. Triad contains carboxymethyl cellulose (CMC) which allows it to adhere to wet, moist, or macerated skin. It contains dimethicone to moisturize the periwound skin and petrolatum and zinc oxide to reduce skin irritation.

Triad is occlusive and creates a barrier to prevent moisture from penetrating through to the skin. Triad is hydrophilic, which means that natural moisture spreads evenly across the wound surface, maximizing contact and creating a moist wound healing environment. CMC allows Triad to absorb low to moderate levels of wound exudate or broken-down tissue. Triad facilitates autolytic debridement by creating a moist wound environment where the body's own enzymes break down necrotic tissue.

What ingredients does Triad contain?

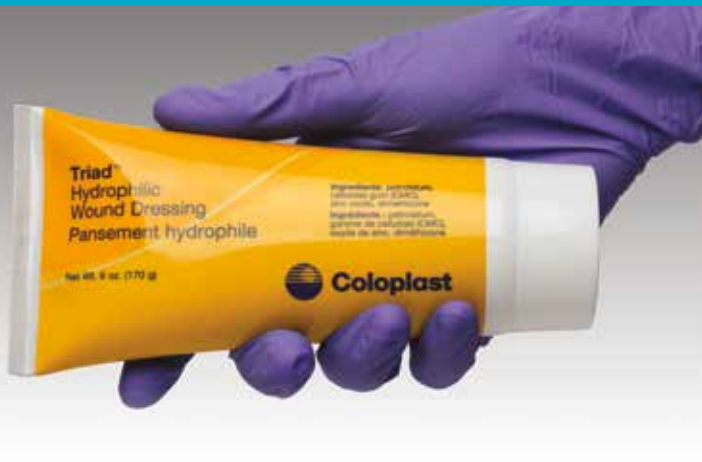Triad contains a unique preservative-free blend of carboxymethyl cellulose (CMC), dimethicone, petrolatum, and zinc oxide. The percentage of each ingredient is proprietary information.

What is the best way to apply and remove Triad?

Always cleanse the wound before applying Triad. Triad can be applied directly from the tube or by using a gloved finger. Gently spread Triad evenly over the area of application to the thickness of a dime. Triad can be used on its own without a secondary dressing. A secondary dressing can be used with Triad when needed based on wound characteristics, amount of exudate and depth. Triad may not always dry completely and some light staining on bed linens or garments might occur. To help prevent staining, cover Triad with a light secondary dressing such as a dry piece of gauze.

For wounds with depth, impregnate gauze with Triad. Fold or fluff the gauze to fit within the wound bed, and loosely pack into the wound and areas of undermining or tunneling. Make sure to place impregnated gauze in such a way that it can easily be removed, and cover the wound with a secondary dressing.

Due to the zinc oxide, Triad should be removed with a commercial wound cleanser. The surfactant in the wound cleanser helps to break down and remove Triad. Use a pH-balanced wound cleanser to soften Triad, and gently wipe to remove without scrubbing. For complete removal repeat as needed. Triad can stay in place for up to seven days, with higher exudate levels requiring more frequent re-applications. In the perineal area, reapply Triad after each episode of incontinence. Triad does not always have to be removed completely before reapplication.



If a secondary dressing is being used with Triad, what type is recommended?

For wounds with depth, where Triad is used with impregnated gauze, the use of a secondary dressing is recommended. In this case a silicone foam dressing could be used. If preferred, to protect Triad from rubbing off on linen or clothing, a dry piece of gauze, a silicone contact layer, or silicone foam dressing could be used.

Can Triad be used on venous leg wounds with weeping periwound skin maceration?

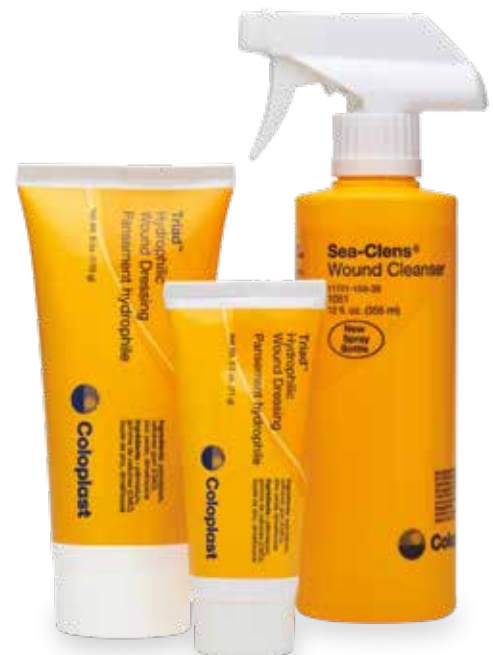Triad can adhere to wet, eroded skin including macerated skin. It has a unique preservative-free blend of ingredients that includes zinc oxide which makes it safe to use on the periwound area and helps to reduce skin irritation. Triad will adhere to weeping skin, although higher levels of exudate will require more frequent re-applications.

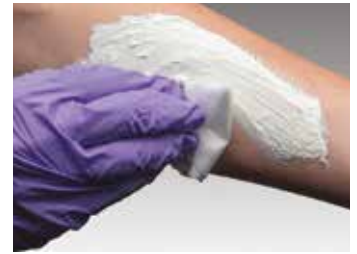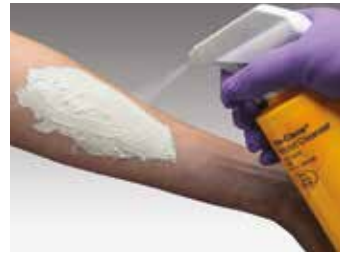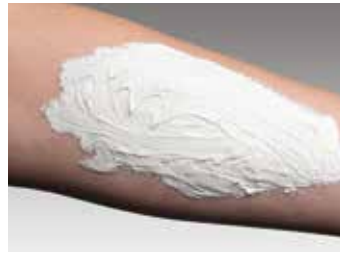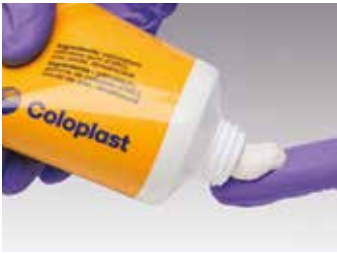Can Triad be used as a skin protectant for patients with incontinence?

Triad may be used when there is a breach in the integrity of the skin or an open area such as a dermal lesion. There is no contraindication to use Triad as a skin protectant. Always refer to your facility protocols for selecting a skin protectant.

Is the use of Triad cost-effective?

On wet or irregular surfaces, dressings may not always stay in place. This could have an impact on the health system, including avoidable costs related to using extra dressings, increased workload for nurses replacing dressings, or delayed wound healing impacting the total cost of care. Refer to our Estimated Savings Guide to calculate potential savings based on information from your facility. Coloplast does not guarantee any amount of cost savings, this tool is for your own facility's estimation purposes only. Prices of Triad may vary locally, contact your local representative for more information.





Triad® instructions for use video:

Scan to view the video:



Ordering Information

Triad can be ordered from most distributors and dealers.
Triad is reimbursed in all care settings.

Triad® Hydrophilic Wound Dressing

Code	Size	Units	HCPS Code
1964	2.5 oz. (71 g)	12	A6240
1967	6 oz. (170 g)	12	A6240



Sea-Cleans® Wound Cleanser

A pH balanced wound cleanser that can be used to remove Triad without scrubbing.

Code	Size	Units	HCPS Code
1063	6 fl. oz. (178 mL)	12	A6260
1061	12 fl. oz. (355 mL)	12	A6260



For more information on adding a Triad to your wound management toolbox or to get connected to a Coloplast representative, [visit TryTriad.com](http://TryTriad.com)

Triad is only sterile on first application.

These materials are intended to be an educational resource for general information purposes only. They are not intended to constitute medical or business advice or in any way replace the independent medical judgment of a trained and licensed physician with respect to any patient needs or circumstances. The information herein may not be representative of all patient outcomes. Each person's situation is unique and risks, outcomes, experience, and results may vary. Please see complete product instructions for use, including all product indications, contraindications, precautions, warnings, and adverse events.

This piece contains Health Economic data and is designed to be used with payors, formulary committees, or similar entities with knowledge of and expertise in the area of health care economic analysis, carrying out its responsibilities for the selection of drugs or devices for coverage or reimbursement.

[Ostomy Care / Contenance Care / Wound & Skin Care / Interventional Urology](#)

Coloplast United States
Minneapolis, MN 55411 / 1-800-533-0464
www.coloplast.us

Coloplast Canada
Oakville, ON L6H 559 / 1-877-820-7005
www.coloplast.ca

